Observational Study

Medicine®

OPEN

Three-dimensional assessment of condylar position following orthognathic surgery using the centric relation bite and the ramal reference line

A retrospective clinical study

Chang-Hyeon Lee, DDS[a,b], Seoung-Won Cho, DDS[a,b], Ju-Won Kim, DDS, PhD[a,b,c], Hyo-Jung Ahn, DDS, PhD[b,c,d], Young-Hee Kim, DDS, PhD[b,c,e], Byoung-Eun Yang, DDS, PhD[a,b,c,*]

Abstract

Orthognathic surgery (OGS) is a relatively common procedure for solving functional and aesthetic problems in facial and jaw areas in patients with dentofacial deformities. The positioning of the mandibular condylar segment during OGS has an impact on the surgical outcome. This study aimed to investigate the changes in the condyle-fossa relationship three dimensionally after OGS using the centric relation (CR) bite and the ramal reference line (RRL).

Thirty-two patients with skeletal malocclusion underwent OGS. Condylar repositioning was performed using the CR bite, as previously reported. A RRL was added to the existing method and used during the surgery. Cone-beam computed tomography scans were acquired at 4 time points. Sixty-four condyles were evaluated in the coronal, sagittal, and axial views. Two groups were created according to the amount of mandible setback (SB1 vs SB2), and another 2 groups were created according to the maxillary operation (1-jaw vs 2-jaw). Each was then compared at the 4 time points. Differences between the values before (T0) and a year after surgery (T3) were also investigated. The positions of the pogonion and the menton were examined at T2 and T3 for the simple evaluation of relapse.

The change in the condylar position was significant over a time-course ($P < .001$) but not between T0 and T3 ($P > .05$). Neither the setback amount nor the maxillary operation affected the positional change ($P > .05$). There were no significant changes between T2 and T3 in the relapse evaluation.

This condylar repositioning method using the CR bite and a RRL showed stable results after OGS. This method is noninvasive and cost-effective and can be easily performed even by an inexperienced surgeon because it reduces errors in repositioning the condyle during OGS.

Abbreviations: 2D = two-dimensional, 3D = three-dimensional, AJS = anterior joint space, CBCT = cone-beam computed tomography, CR = centric relation, IVRO = intraoral vertical ramus osteotomy, LJS = lateral joint space, MJS = medial joint space, OGS = orthognathic surgery, PJS = posterior joint space, RRL = ramal reference line, SJS = superior joint space, SSO = sagittal split ramus osteotomy, TMD = temporomandibular disorder, TMJ = temporomandibular joint.

Keywords: cone-beam computed tomography, craniofacial, orthognathic

1. Introduction

Orthognathic surgery (OGS) is a relatively common procedure for solving functional and aesthetic problems in facial and jaw areas in patients with dentofacial deformities. The positioning of the mandibular condylar segment during OGS has an impact on the surgical outcome. After sagittal split ramus osteotomy (SSO) of the mandible was presented by Obwegeser,[1] many surgeons have strived to maintain the proximal segment (mandibular condyle bearing segment) in the centric relation (CR) position, which is the most stable position for the condyle, in the glenoid fossa even though this remains controversial.[2] The CR position

Editor: Yan Li.

This study was approved by the institutional review board of Hallym University Sacred Heart Hospital (IRB No. 2018-I009). All of the clinical studies were performed in accordance with the relevant guidelines and regulations. Retrospective unnamed data were collected for comparative purposes.

The authors have no funding and conflicts of interest to disclose.

All data generated or analyzed during this study are included in this published article (and its supplementary information files).

[a] Department of Oral and Maxillofacial Surgery, Hallym University College of Medicine Sacred Heart Hospital, Anyang-Si, [b] Graduate School of Clinical Dentistry, [c] Institute of Clinical Dentistry, Hallym University, Chuncheon, [d] Department of Orthodontics, [e] Department of Image Science in Dentistry, Hallym University College of Medicine Sacred Heart Hospital, Anyang-Si, Republic of Korea.

[*] Correspondence: Byoung-Eun Yang, Department of Oral and Maxillofacial Surgery, Hallym University College of Medicine Sacred Heart Hospital, 11, Gwanpyeong-ro 170beon-gil, Dongan-gu, Anyang-si, Gyeonggi-do 14066, Republic of Korea (e-mail: omsyang@gmail.com, face@hallym.or.kr).

Copyright © 2019 the Author(s). Published by Wolters Kluwer Health, Inc.
This is an open access article distributed under the terms of the Creative Commons Attribution-Non Commercial-No Derivatives License 4.0 (CCBY-NC-ND), where it is permissible to download and share the work provided it is properly cited. The work cannot be changed in any way or used commercially without permission from the journal.

Medicine (2019) 98:12(e14931)

Received: 18 October 2018 / Received in final form: 28 February 2019 / Accepted: 28 February 2019

http://dx.doi.org/10.1097/MD.0000000000014931

Downloaded from https://journals.lww.com/md-journal by BhDMf5ePHKav1zEoum1tQfN4a+kJLhEZgbsIHo4XMi0hCywCX1AWnYQp/IlQrHD3cgoVWF5HHNPvQJmBDb5zU+uhZSqUXAZ4p1p0NN4T3ZADf3IlNOxg== on 03/26/2019

is the most retruded, unstrained position of the condyle within the temporomandibular joint (TMJ), that is, within the glenoid fossa. Ideally, in centric occlusion, the condyle sits anatomically within the glenoid bilaterally, reflecting simultaneous centric occlusion and CR.[3] The position of the condyle may change due to various causes after OGS. Intraoperatively, the supine position of a patient can induce the posterior derangement of the mandible due to gravity.[4] General anesthesia also contributes to posterior derangement due to the relaxation of muscles around the joint.[5] Condylar misplacement during surgery results in displacement of the condyle and induces the pathological resorption of the condyle, decreased mouth opening, and clicking or popping sound from the TMJ.[6] With the prolonged loss of the CR position, the distracting forces may lead to some muscular, soft tissue, and bony pathological changes around the TMJ. Several methods have been claimed to keep the condyle in a stable position during OGS. In 1976, a condylar positioning device was first introduced.[7] Since then, various devices have been devised for condylar positioning during OGS. A procedure using a three-dimensional (3D) optical localizer to establish the position of the condylar segment was reported by Bettega et al.[8] Harada et al introduced a clamp system for repositioning the proximal segment with 1 main splint and 3 minisplints.[9] Yagami et al presented a repositioning method utilizing an occlusal splint, arch bar with acrylic blocks and positioning plate system composed of some screws, an acrylic block, and a positioning plate.[10] However, the methods used in these reports are time-consuming and require many accessories. Additionally, the reference points of the condylar position were not accurate for several reasons. In the state of unconsciousness, the condylar position significantly changes.[5] In our previous study, we obtained the CR bite in a conscious state and used it for OGS.[11,12] However, at the time of reporting, we used a two-dimensional (2D) image to trace the position of the condyle for a relatively short period. Therefore, this study was conducted to trace the condylar position in 3D using CBCT for over a year. This study aimed to use CBCT to evaluate the postoperative positional changes of the condyle in patients with skeletal malocclusion who underwent OGS using the CR bite and the ramal reference line (RRL).

2. Methods

2.1. Subjects

The inclusion criteria were as follows:

1. patients who underwent surgery between September 2013 and December 2016;
2. those with presurgical orthodontics; and
3. those with skeletal class III malocclusion with ANB $\leq 0°$.

On the other hand, patients with cleft palate or craniofacial anomalies, those who underwent intraoral vertical ramus osteotomy (IVRO), and those with 4 degrees of occlusal canting[13] were excluded. The number of patients who were eligible for inclusion was 32 (12 men and 20 women; mean age, 24 ± 3.5 years). A total of 16 patients underwent a mandible-only operation, and 16 patients further underwent a conventional LeFort I osteotomy. Bilateral SSO was performed using the Obwegeser[1] technique with the Wolford modification.[14] A single surgeon operated on all the patients. We divided the group according to the amount of mandibular movement (SB1 versus SB2) and the maxillary operation (1-jaw versus 2-jaw). The SB1 group (n = 13) had mandibular movement less than 5 mm, while the SB2 group (n = 19) had mandibular movement greater than 5 mm. The amount of mandibular movement was measured by the distance (parallel to the Frankfort plane) between each mandibular anterior tip after superimposition of the preoperative and postoperative CBCT scans. We assigned "2-jaw" to the group that underwent LeFort I osteotomy simultaneously with SSO (n = 16). All medical records and radiographs were analyzed. Approval for this study was granted by the Hallym University Sacred Heart Hospital's institutional review board (IRB No. 2018-I009). Our institutional review board approved this retrospective study and informed consent was waived by the study subjects, as all the patient data were anonymized and de-identified before the analysis.

2.2. Surgical procedures

The condylar repositioning method during OGS was as follows. We have previously reported this method[11,12] and have made some modifications in this study. The patient's CR bite was attained the day before surgery using Dawson's bilateral manipulation method.[15] Then, the procedure proceeded as follows for mandible-only surgery (Fig. 1). After general anesthesia, the osteotomy was performed on the mandible. The CR bite obtained on the day before surgery was inserted into the oral cavity before the separation of the proximal and distal segments. An extension line (IV: RRL) was drawn with a medical pencil on the buccal surface of the ramus parallel to the orthodontic wire on the maxilla. A hole marking (II) with a 2-mm-diameter round bur was made at the anterior end of the extension line. A rigid wire with a length reaching from the II site to one of the maxillary posterior tooth brackets was created. The position of this maxillary posterior tooth bracket was designated I. A hole (III) was made equal to the distance from I to II at a position of 5 to 6 mm downward from II. Each wire was prepared for both the left and the right (Fig. 1B). After bone separation, the final wafer was mounted, and the maxillomandibular fixation was performed with rubber. Before fixing the proximal and distal segments with a miniplate, the following features were checked. The position of the proximal segment was confirmed to be parallel and of the same height as the RRL and the orthodontic wire on the maxilla, and the length between each reference point was checked to determine whether the prepared rigid wire was fitted correctly. After confirming that all features were correct, the proximal and distal segments were fixed with a miniplate (Fig. 1C).

In the case of a bimaxillary surgery, the operation proceeded as follows. After the osteotomy was performed in the mandible, the proximal and the distal segments were left unseparated. The mucoperiosteum of the maxilla was elevated, and the maxillary bone was exposed. Then, the prepared CR bite was placed in the patient's mouth. A reference hole (①) was made with a round bur on the upper part of the LeFort I osteotomy line. Similar to the mandible-only surgery, reference holes (② and ③) were formed in the anterior border of the ramus using the distance of the rigid wire (Fig. 2A). After the LeFort I osteotomy, the intermediate wafer was inserted with the maxilla moving. After the maxilla was moved into the planned position, it was fixed with 4 L-plates. In this state, the mandible was closed so that the prepared rigid wire met the distance between the reference points. Then, a line (④: RRL) was drawn on the buccal surface of the ramus using a pencil at the height and position parallel to the orthodontic wire on the maxilla (Fig. 2B). A final wafer was inserted into the mouth after the proximal and distal segments of the mandible were separated. Then, whether the RRL and the

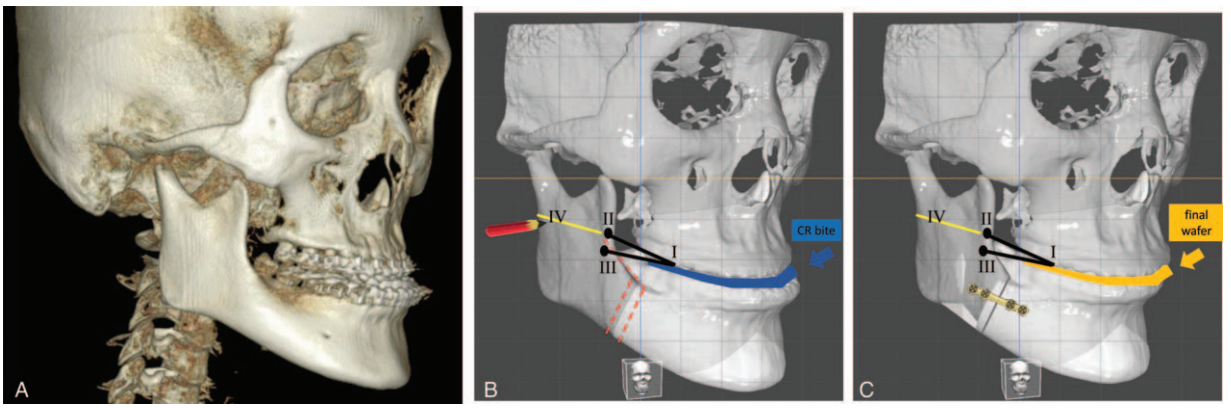

Figure 1. Illustration of condylar positioning method during mandible-only surgery. (A) Preoperative view in a 24-year-old patient with mandibular prognathism. (B) The CR bite (blue arrow) was inserted before the separation of the mandibular bone segments. An extension line (IV: RRL) was drawn on the buccal surface of the ramus parallel to the orthodontic wire on the maxilla. A hole marking (II) was made at the anterior end of the RRL. A rigid wire with a length from the II site to the maxillary posterior tooth bracket was created. The position of this maxillary posterior tooth bracket was designated I. A hole (III) was made equal to the distance from I to II at the position 5 to 6 mm downward from II (I to II is equal I to III). (C) After bone separation, the final wafer (yellow arrow) was mounted, and maxillomandibular fixation was performed. Whether the position and parallelism of the RRL and the distance between each reference point was the same as when the CR bite was inserted was verified. The separated bone segments were fixed with a miniplate. CR = centric relation, RRL = ramal reference line.

maxillary orthodontic wire were parallel at the same height and whether the length of the rigid wire was equal to the distance between each reference point were verified (Figure 2C).

2.3. Analysis of the CBCT images and mandibular relapse

3D images were obtained before the surgery (T0) and at 3 days (T1), 4 months (T2) and 1 year (T3) postoperatively by CBCT (Alphard 3030; Asahi Inc., Kyoto, Japan). All the images were obtained using the following settings: 80 kVp, 5 mA, and an exposure time of 17 seconds. Images were transformed into the DICOM format and three-dimensionally reconstructed and analyzed using OnDemand 3D software (Cybermed, Seoul, Korea). The images were reoriented along the Frankfort plane on the basis of the right porion, right orbitale, and left orbitale. Then, the vertical midline and horizontal reference planes were set accordingly. Slices of coronal, sagittal and axial images were selected for each patient during the follow-up periods (Fig. 3). For the coronal image, measurements were made as shown in Figure 4A. The medial joint space (MJS) and lateral joint space (LJS) were measured from the most prominent medial and lateral condylar points to the glenoid fossa. For the sagittal image, measurements were made as shown in Figure 4B. The linear measurements of the right and left joint spaces were assessed, and the anterior joint space (AJS), superior joint space (SJS), and posterior joint space (PJS) were measured from the most prominent anterior, posterior, and superior condylar points to the glenoid fossa. The plane parallel to the Frankfort plane was used as the reference plane. In the axial view, the angle (θ) between the line connecting the medial pole and lateral pole of the condyle and perpendicular to the midpoint of the axial surface was measured (Fig. 4C). For a brief evaluation of the relapse of

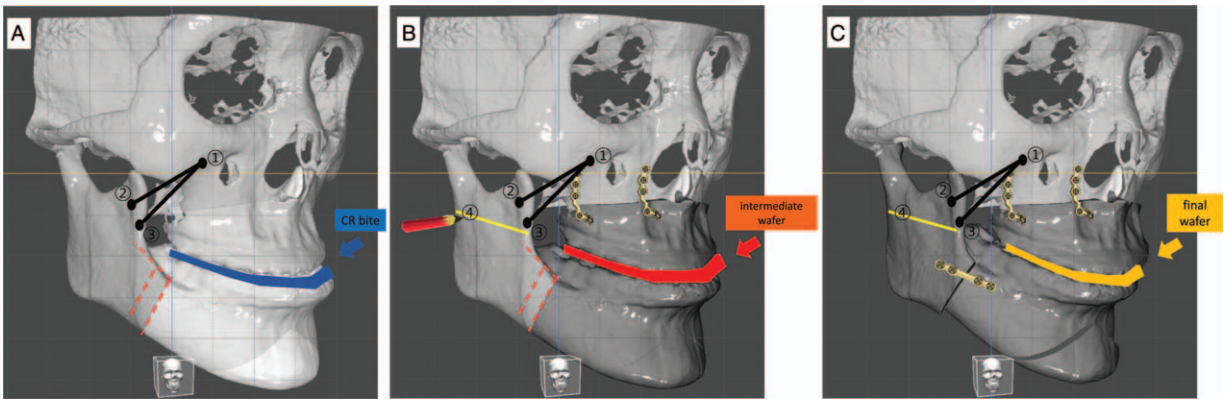

Figure 2. Illustration of condylar positioning method during bimaxillary surgery. If the patient in Figure 1A required bimaxillary surgery: A, After the osteotomy was performed in the mandible, the proximal and distal segments were left unseparated. The CR bite (blue arrow) was placed. A reference hole (①) was made on the upper part of the LeFort I osteotomy line (the maxillary area that does not move during OGS). Reference holes (② and ③) were formed in the anterior border of the ramus similar to mandible-only surgery. B, After LeFort I osteotomy, the intermediate wafer (red arrow) was inserted. After the maxilla was moved to the planned position, it was fixed with L-miniplates. In this state, the mandible was closed so that the prepared rigid wire met the distance between the reference points. Then, a line (④: RRL) was drawn on the ramus buccal surface at a height and a position parallel to the orthodontic wire of the maxilla. C, After the segments of the mandible were separated, a final wafer (yellow arrow) was inserted. The RRL parallelism and equal distances between each reference point were verified. The separated mandibular bone segments were fixed with a miniplate. CR = centric relation, OGS = orthognathic surgery, RRL = ramal reference line.

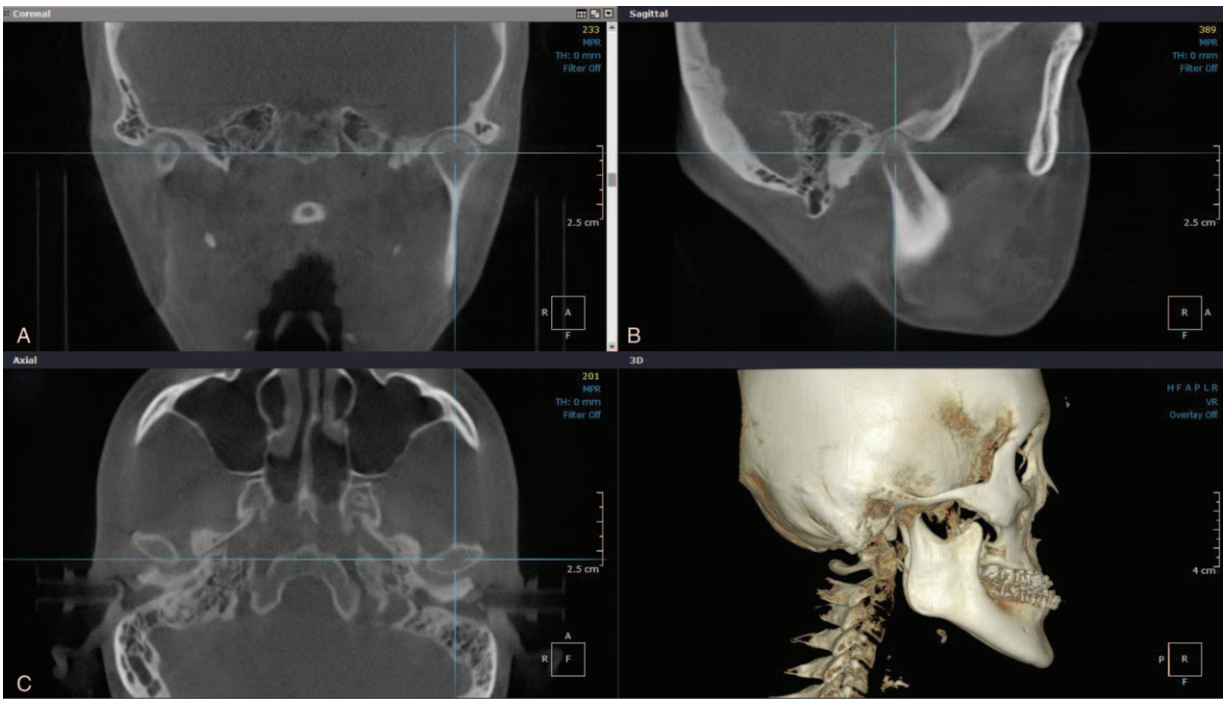

Figure 3. CBCT image of the condyle: A, coronal view; B, sagittal view; and C, axial view. The CBCT images were reoriented with the horizontal reference plane connecting the bilateral orbitales, and the Frankfort horizontal plane and the vertical midline and horizontal reference planes were set accordingly. The sagittal slice (B) was evaluated at the point where the mediolateral diameter of the right or left condyles was greatest (C) in the axial view. CBCT = cone-beam computed tomography.

the mandible position, the pogonion and menton positions were measured at T2 and T3. The amount of relapse was obtained by measuring the distance from pogonion to the nasion perpendicular line. The position of menton was measured by the vertical linear distance in the horizontal reference line (Fig. 5). Two doctors performed the measurements, and the distance and angle were calculated as the averages of their measurements.

2.4. Statistics

For a total of 64 condyles from 32 patients, the distance between the condyle and fossa, and the degree of condylar rotation were analyzed. For the statistical analysis, repeated measures ANOVA was used to investigate the interaction between the time course and the groups, despite the small sample size. Nonparametric statistical tests were used to assess differences between T0 and T3 due to the small sample size. Wilcoxon signed-rank tests were used to determine differences between T0 and T3. A Mann–Whitney *U* test was used to compare the changes between subgroups in T0 and T3. Comparisons of the menton and pogonion positions obtained at T2 and T3 were analyzed using Wilcoxon signed-rank tests. SPSS 12.0 (SPSS Inc., Chicago, IL) was used for statistical analysis. In each analysis, $P < .05$ was considered to represent significance.

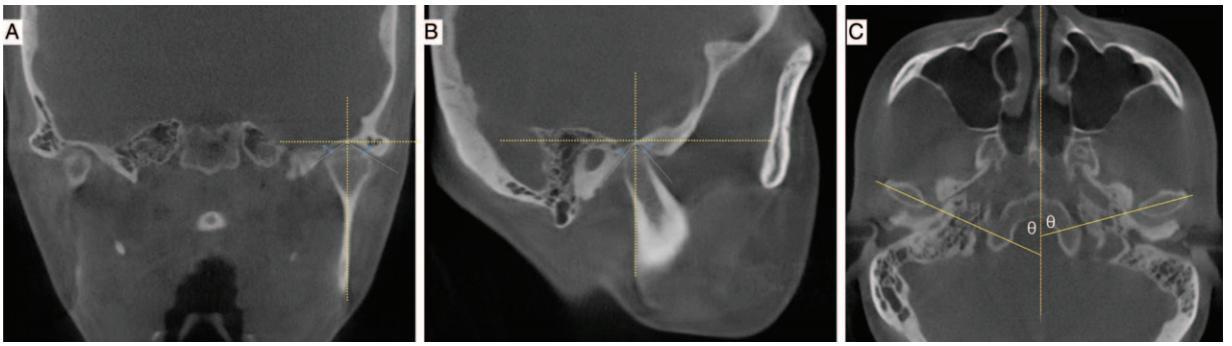

Figure 4. Measurement of the condyle-fossa relationship. (A) Measurement of the joint space in the coronal view. The medial joint space (MJS) and lateral joint space (LJS) were measured from the most prominent medial and lateral condylar points to that of the glenoid fossa. (B) Measurement of the joint space in the sagittal view. The anterior joint space (AJS), superior joint space (SJS), and posterior joint space (PJS) were measured from the most prominent anterior, posterior, and superior condylar points to that of the glenoid fossa. The plane parallel to the Frankfort horizontal plane was used as the reference plane. (C) Measurement of the condylar angle of the condylar process (θ). This angle was defined as the angle between the long axis of the mandibular condylar process and a perpendicular line to the midsagittal plane.

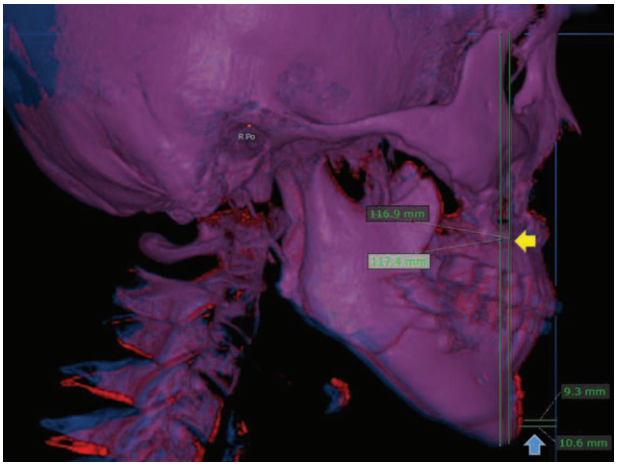

Figure 5. CBCT scans at T2 (blue color) and T3 (red color). After CBCT reorientation (patient in Figure 1A), the menton and pogonion positions were measured at each reference line. The menton was 117.4 mm (at T2) and 116.9 (at T3) (yellow arrow), and the pogonion was −10.6 (at T2) and −9.3 (at T3) mm (blue arrow) from each reference line. CBCT = cone-beam computed tomography.

3. Results

The mean data of the condylar position and the standard deviation were calculated. Analysis of alterations in the condylar position from T0 to T3 with repeated measures ANOVA is shown in Tables 1 and 2. Alterations were significant regarding time, from T0 to T3, in all dimensions in both groups ($P<.001$). The setback amount did not have a significant effect on condylar position alterations ($P>.05$). The mean amounts of mandibular setback were 5.95±2.44 mm for all patients, 3.60±0.95 mm in the SB1 group, and 7.56±1.72 mm in the SB2 group. There was no interaction between the time course and setback amount ($P>.05$) (Table 1). The maxillary operation did not affect the condylar position change ($P>.05$). There was no interaction between the time-course and jaw group except SJS and PJS ($P>.05$) (Table 2). Tables 3 and 4 show the results of the statistical analysis of the changes between T0 and T3 in the 2 groups created according to the amount of movement of the distal segment and the 2 groups created according to the maxillary surgery. There were no significant changes in the condylar position in any dimension ($P>.05$) except for LJS in the SB2 group ($P=0.025$), AJS in SB1 group ($P=0.034$), and LJS in the 1-jaw group ($P=0.025$). There were no significant differences in the pogonion and menton locations between T2 and T3 ($P>.05$) (Table 5).

4. Discussion

In repositioning the maxillary or the mandibular arches, it is critical not to overlook the concept of the CR position while focusing primarily on achieving centric occlusion. Therefore, when repositioning the jaws, the surgeon must make sure that the condyle is appropriately seated within the fossa before initiating rigid bony fixation.[3] We have previously reported the study of condylar position changes using 2D radiographs.[11,12] However, in the study using 2D radiographs, the anatomical structures are often overlapped, and it is difficult to display the correct anatomical points. In addition, it is also difficult to reproduce the same points each time in the same patient. Currently, 3D CBCT is the primary choice for orthodontic diagnosis and orthognathic planning due to its acceptable cost and low radiation. With CBCT, it is possible to measure each reference point or line with more accuracy and obtain necessary values in the coronal and

Table 1

Statistical analysis of the condylar position according to the amount of setback movement in the coronal, sagittal and axial views at T0, T1, T2, and T3.

		T0 Mean±SD	T1 Mean±SD	T2 Mean±SD	T3 Mean±SD		F	P
MJS	SB1	1.96±0.54	3.25±1.3	2.12±0.74	1.95±0.55	Time	21.675	<.001
						setback	0.66	ns
						time*setback	0.315	ns
	SB2	2.22±1.13	3.42±1.46	2.22±0.77	2.06±0.67			
LJS	SB1	1.8±0.77	2.88±1.1	1.99±0.6	1.9±0.53	Time	20.416	<.001
						setback	0.01	ns
						time*setback	0.294	ns
	SB2	1.84±0.78	2.7±1.43	2.11±0.6	1.99±0.63			
AJS	SB1	1.75±0.54	2.37±0.76	2.03±0.63	1.89±0.51	Time	14.477	<0.001
						setback	0.409	ns
						time*setback	0.146	ns
	SB2	1.87±0.65	2.46±0.77	2.11±0.53	1.94±0.52			
SJS	SB1	2.31±0.88	3.58±1.14	2.54±0.75	2.27±0.79	Time	23.127	<.001
						setback	0.092	ns
						time*setback	0.88	ns
	SB2	2.47±1.09	3.32±1.08	2.69±0.78	2.47±0.87			
PJS	SB1	2.1±0.87	3.26±1.44	2.2±0.77	2.1±0.72	Time	11.982	<.001
						setback	0.895	ns
						time*setback	1.818	ns
	SB2	2.02±0.93	2.67±0.95	2.24±0.74	2.06±0.67			
ANGLE	SB1	70.24±6.59	65.77±7.38	67.46±6.43	70.4±6.7	Time	18.32	<.001
						setback	0.089	ns
						time*setback	0.264	ns
	SB2	69.47±6.15	65.07±7.32	67.53±6.23	70.11±5.91			

AJS = anterior joint space, LJS = lateral joint space, MJS = medial joint space, ns = not-significant, PJS = posterior joint space, SJS = superior joint space.

Table 2

Statistical analysis of the condylar position with maxillary operation in the coronal, sagittal and axial views at T0, T1, T2, and T3.

	Jaw group	T0 Mean±SD	T1 Mean±SD	T2 Mean±SD	T3 Mean±SD		F	P
MJS	1-jaw	1.96±0.64	2.94±1.39	1.97±0.55	1.92±0.55	Time	23.644	<.001
						jaw	5.601	0.02
						time*jaw	1.687	ns
	2-jaw	2.26±1.16	3.76±1.28	2.39±0.88	2.11±0.69			
LJS	1-jaw	1.68±0.71	2.66±1.17	1.95±0.51	1.86±0.58	Time	20.483	<.001
						jaw	1.829	ns
						time*jaw	0.23	ns
	2-jaw	1.96±0.82	2.89±1.43	2.16±0.66	2.04±0.59			
AJS	1-jaw	1.79±0.53	2.25±0.71	2.05±0.56	1.85±0.44	Time	15.167	<.001
						jaw	1.45	ns
						time*jaw	1.269	ns
	2-jaw	1.86±0.69	2.6±0.78	2.11±0.59	1.98±0.57			
SJS	1-jaw	2.32±1.03	2.95±0.72	2.51±0.83	2.3±0.84	Time	24.588	<.001
						jaw	2.406	0.05
						time*jaw	3.12	0.033
	2-jaw	2.49±0.99	3.9±1.22	2.75±0.69	2.47±0.84			
PJS	1-jaw	2.12±0.98	2.66±0.93	2.1±0.8	2.1±0.8	Time	11.571	<.001
						jaw	0.623	ns
						time*jaw	2.963	0.039
	2-jaw	1.98±0.82	3.16±1.38	2.34±0.68	2.05±0.56			
ANGLE	1-jaw	69.61±5.9	64.79±7.44	66.55±6.43	70.36±6.03	Time	19.16	<.001
						jaw	0.315	ns
						time*jaw	0.886	ns
	2-jaw	69.96±6.75	65.92±7.22	68.45±6.03	70.1±6.43			

AJS=anterior joint space, LJS=lateral joint space, MJS=medial joint space, ns=not-significant, PJS=posterior joint space, SJS=superior joint space.

axial sections. In this study, it was possible to determine how much the condylar position was altered more precisely in every dimension and at every time point using CBCT. The position of the condyle significantly varied according to the time-course. Unlike the other time points, the most significant difference was found at T1. This differs from the other time points is probably

Table 3

Statistical analysis between T0 and T3 according to the amount of setback movement.

	Setback group	T0 mean±SD	T3 mean±SD	Within group Z	Within group P	Between group Z	Between group P
MJS	SB1	1.96±0.54	1.95±0.55	−0.476	ns	−0.559	ns
	SB2	2.22±1.13	2.06±0.67	−0.206	ns		
LJS	SB1	1.8±0.77	1.9±0.53	−1.876	ns	−0.529	ns
	SB2	1.84±0.78	1.99±0.63	−2.239	0.025		
AJS	SB1	1.75±0.54	1.88±0.51	−2.121	0.034	−0.836	ns
	SB2	1.87±0.65	1.94±0.52	−1.102	ns		
SJS	SB1	2.31±0.88	2.27±0.79	−0.212	ns	−0.721	ns
	SB2	2.47±1.09	2.47±0.87	−0.518	ns		
PJS	SB1	2.1±0.87	2.1±0.72	−0.217	ns	−0.534	ns
	SB2	2.02±0.93	2.06±0.67	−0.447	ns		
ANGLE	SB1	70.24±6.59	70.4±6.7	−0.394	ns	−0.492	ns
	SB2	69.47±6.15	70.11±5.91	−0.075	ns		

AJS=anterior joint space, LJS=lateral joint space, MJS=medial joint space, ns=not-significant, PJS=posterior joint space, SJS=superior joint space.

Table 4

Statistical analysis between T0 and T3 according to maxillary surgery.

		T0	T3	Within group		Between group	
	Jaw group	Mean ± SD	Mean ± SD	*Z*	*P*	*Z*	*P*
MJS	1-jaw	1.96 ± 0.64	1.92 ± 0.55	−0.691	ns	−1.067	ns
	2-jaw	2.26 ± 1.16	2.11 ± 0.69	−0.069	ns		
LJS	1-jaw	1.68 ± 0.71	1.86 ± 0.58	−2.239	0.025	−1.961	ns
	2-jaw	1.96 ± 0.82	2.04 ± 0.59	−1.785	ns		
AJS	1-jaw	1.79 ± 0.53	1.85 ± 0.44	−1.616	ns	−0.535	ns
	2-jaw	1.86 ± 0.69	1.98 ± 0.57	−1.582	ns		
SJS	1-jaw	2.32 ± 1.03	2.3 ± 0.84	−0.08	ns	−1.061	ns
	2-jaw	2.49 ± 0.99	2.47 ± 0.84	−0.23	ns		
PJS	1-jaw	2.12 ± 0.98	2.1 ± 0.8	−0.394	ns	−0.076	ns
	2-jaw	1.98 ± 0.82	2.05 ± 0.56	−1.172	ns		
ANGLE	1-jaw	69.61 ± 5.9	70.36 ± 6.03	−0.262	ns	−0.036	ns
	2-jaw	69.96 ± 6.75	70.1 ± 6.43	−0.137	ns		

AJS = anterior joint space, LJS = lateral joint space, MJS = medial joint space, ns = not-significant, PJS = posterior joint space, SJS = superior joint space.

due to the edema immediately after the operation, the thickness of the wafer, and the unfavorable adaptation of the muscles around the joints. Fernandez et al verified intra-articular edema using magnetic resonance imaging during the early postoperative period in patients after mandibular subcondylar osteotomy.[16] The observed difference between the use of a wafer after the surgery and the final occlusion in 1 study[17] could also be a factor. Based on the case, this factor can be eliminated by not using a wafer after the surgery. If a wafer is necessary, minimizing its thickness will help decrease the rotational error that can occur.

We examined the effect of the distal segment movement and maxillary operation on the time-course. Therefore, no posthoc test was performed for each time difference. There was no interaction between the group and time-course in the 2 groups created by 2 criteria except SJS and PJS in the jaw group. We wanted to exclude factors that could affect the condyle-fossa relationship immediately after the surgery, including wafer use. For this reason, we performed Wilcoxon signed-rank tests to compare between T0 and T3. The condylar position was not significantly different between T0 and T3 in most of the dimensions. This result shows that the condyle-fossa relationship before surgery was maintained until the first year after the surgery through our condylar positioning method. By moving the distal segment, the neuromuscular balance may have been altered by stretching the connective tissues within the muscle and tendinous attachments to the bone. Whether the setback amount affects the stability of the proximal segment is considered controversial. There are many studies on the relationship between the amount of mandibular movement and postoperative relapse. However, there are few studies on the relationship between the condylar position and mandibular movement. Kang et al reported that the condylar displacement regarding the amount of backward movement of the mandible was significant, primarily when it was greater than 10 mm of setback.[18] Mendez-Manjon et al found a positive correlation between the displacement of the condyle and the amount of mandibular advancement using CBCT.[19]

In this study, the setback amount did not alter the condylar position. There were 2 patients with a mandibular displacement of more than 10 mm. There was no significant change in the condylar location in these patients. There were no interactions between the divided groups according to the amount of movement of the distal segment and time-course. We also wondered how the condylar position was affected when performing the bimaxillary surgery. Kim et al claimed that the condylar displacement in both the single and double-jaw groups was clinically insignificant.[20] In our study, there were no differences in the condyle-fossa relationship over time in the

Table 5

Statistical analysis of menton (Me) and pogonion (Pg) changes between T2 and T3.

	T2	T3	*Z*	*P*
Horizontal reference line-Me	123.26 ± 6.18	122.96 ± 6.29	−0.574	ns
Nasion perpendicular-Pg	−3.82 ± 6.26	−3.64 ± 6.20	−0.065	ns

ns = not-significant.

single or double-jaw groups, despite the difference in the condylar positioning method between the groups.

There have been several studies on the effects of ramus osteotomy on the temporomandibular disorder (TMD). Takahara et al found no significant correlation between the mandibular setback using bilateral SSO and postoperative TMD symptoms.[21] Panula et al reported that TMJ symptoms disappeared after SSO and that the risk for new TMD was extremely low.[22] IVRO has been demonstrated to improve TMJ symptoms, including sounds and pain.[23] However, comparing the preoperative and postoperative statuses, neither technique achieves an increase in the interincisal width during maximum jaw opening.[24] In this study, 6 patients had existing TMD before surgery. No statistical analysis was performed according to TMD due to the small number of patients. At the time of T3, no patients complained of joint symptoms. Our condylar repositioning method cannot be interpreted as solving TMD, but it did not cause new joint problems. It is generally conceded that compared with IVRO, surgeons have better control of the condylar segment during surgery when bilateral SSO is used.[25] When IVRO is performed, the surgeon cannot control the position of the condyle during surgery because the proximal segment and the distal segment are generally not fixed to each other. Therefore, patients who underwent IVRO were excluded from the study.

Many condylar repositioning techniques have been introduced to date. Some techniques are precise but require much effort and are costly. In this study, just 1 CR bite, 2 wires (right and left sides), and an RRL were used. In this study, we made the reference line by drawing a horizontal line parallel to the maxillary orthodontic wire on the buccal surface of the ramus to make the 3D repositioning of the condyle more accurate. In the case of the bimaxillary surgery, this reference line could not be drawn with the condyle in the CR position, but it was of additional help in repositioning the proximal segment. The condylar location was not different between the 1-jaw group and the 2-jaw group. Mobarak et al reported that counterclockwise rotation of the ramus leads to instability because the subsequently altered muscle orientation tends to return the proximal segment to its original inclination.[26] By marking the RRL during surgery, we were able to maintain a ramal inclination similar to that before surgery even after surgery. In the relapse-related evaluation of pogonion and menton location changes between T2 and T3, it was assumed that the condyle-fossa relationship was stabilized as the bone healed there were no significant differences between the 2 time points.

We are aware that our research may have limitations. First, the small sample size limits the ability to draw the strong results. One reason for the small sample size was the utilization of strict inclusion and exclusion criteria, which resulted in exclusion of the majority of the orthognathic surgeries completed in the department during the study period. We excluded patients with facial asymmetry with an occlusal cant greater than 4 degrees. These patients may not have a normal ramus flare and may require repositioning of the proximal segment location, which is different from that in the preoperative state. Ueki et al suggested that the preoperative position of the condyle was not the desired postoperative position in OGS.[27] We agree with this opinion. Therefore, patients suspected of having severe facial asymmetry or TMJ deformations were excluded from the study. In these patients with severe asymmetry, virtual surgery may be used to reset the proximal segment and to reflect this in the actual operation. Second, there were few patients with TMD in this study, but there was a possibility that they had an unhealthy condylar position before the surgery. Therefore, follow-up studies are needed in many patients with TMD in the future. Third, left and right TMJ can affect each other because they work simultaneously when they function unlike other joints in the body. However, this study excluded patients with severe asymmetry with different condyle sizes. In the present study, we assumed that the joints were independent of one another, but they may affect each other. Therefore, further evaluation will be needed in the future. Fourth, because only the skeletal position was investigated in this study, further studies on the muscle, ligament and articular disc around the TMJ using MRI will be needed. Last, there are controversies regarding the use of devices in condylar repositioning. Costa et al reported that there is no scientific evidence to support the routine use of condylar positioning devices in the OGS.[28] They noted that condylar repositioning is possible with only the surgeon's skill and that the complexity and cost increase with the application of these devices.[28] However, the method we use is noninvasive and requires less time to apply and check the proper condylar position, which does not increase the operation time and is not costly. Some researchers have reported that there is no ideal position of the condyle in the glenoid fossa, but there is rather a range of the normal position.[29,30] We agree with this report. Our technique does not guarantee the complete 3D positioning of the condyle during OGS. A skilled surgeon may not have to use this method, but a less experienced surgeon could make fewer surgical errors using this method. This technique will allow the condyle to be seated in the glenoid fossa within a range that is not clinically problematic.

5. Conclusion

Measurement of the condylar position by CBCT at 1 year after surgery revealed no significant changes from the preoperative condylar position. The condyle-fossa relationship at 1 year after surgery was similar to that before surgery regardless of the mandibular movement or maxillary operation. Various factors can change the condyle-fossa relationship, but the method we describe is a condylar repositioning method that can be applied quickly and predictably by inexperienced surgeons during OGS.

Acknowledgments

The authors like to thank the manager of the FaceGide team, Chun-Gi Jeong MDT, for the 3D images (Figs. 1B, C and 2) work. The authors would like to thank Dr. Jun-Young You, PhD, (Director of "Gnatho Oral and Maxillofacial Surgery Clinic," Seoul, Republic of Korea) for advice on the techniques of OGS.

Author contributions

Conceptualization: Chang-Hyeon Lee, Ju-Won Kim, Hyo-Jung Ahn, YoungHee Kim, ByoungEun Yang.
Data curation: Seoung-Won Cho, Ju-Won Kim, YoungHee Kim.
Formal analysis: ByoungEun Yang.
Investigation: Seoung-Won Cho, ByoungEun Yang.
Project administration: ByoungEun Yang.
Software: Seoung-Won Cho.
Supervision: Ju-Won Kim, Hyo-Jung Ahn, ByoungEun Yang.
Validation: Ju-Won Kim, Hyo-Jung Ahn, YoungHee Kim, ByoungEun Yang.
Writing – original draft: Chang-Hyeon Lee, ByoungEun Yang.

Writing – review & editing: Ju-Won Kim, Hyo-Jung Ahn, YoungHee Kim, ByoungEun Yang.

ByoungEun Yang orcid: 0000-0002-4446-6772.

References

[1] Trauner R, Obwegeser H. The surgical correction of mandibular prognathism and retrognathia with consideration of genioplasty: Part I. Surgical procedures to correct mandibular prognathism and reshaping of the chin. Oral Surg Oral Med Oral Pathol 1957;10:677–89.

[2] Keshvad A, Winstanley R. An appraisal of the literature on centric relation. Part II. J Oral Rehab 2000;27:1013–23.

[3] Stotland MA, Kawamoto HK. Principles of orthognathic surgery. Plastic Surgery Secrets Plus 2nd ed: Elsevier 2010;187–91.

[4] Boucher L, Jacoby J. Posterior border movements of the human mandible. J Prosthet Dent 1961;11:836–41.

[5] McMillen LB. Border movements of the human mandible. J Prosthet Dent 1972;27:524–32.

[6] Hoppenreijs TJ, Stoelinga PJ, Grace KL, et al. Long-term evaluation of patients with progressive condylar resorption following orthognathic surgery. Int J Oral Maxillofac Surg 1999;28:411–8.

[7] Leonard M. Preventing rotation of the proximal fragment in the sagittal ramus split operation. J Oral Surg 1976;34:942–1942.

[8] Bettega G, Dessenne V, Raphael B, et al. Computer-assisted mandibular condyle positioning in orthognathic surgery. J Oral Maxillofac Surg 1996;54:553–8.

[9] Harada K, YO , Nagura H, et al. A new appliance for condylar. Int J Oral Maxillofac Surg 1995;24:342–3.

[10] Nagumo KYAM. A transoral approach for threedimensional repositioning of the proximal segment after mandibular sagittal split ramus osteotomy. J Oral Maxillofac Surg 1996;54:1256–8.

[11] Oh SM, Lee CY, Kim JW, et al. Condylar repositioning in bilateral sagittal split ramus osteotomy with centric relation bite. J Craniofac Surg 2013;24:1535–8.

[12] Lee CY, Jang CS, Kim JW, et al. Condylar repositioning using centric relation bite in bimaxillary surgery. Korean J Orthod 2013;43:74–82.

[13] Padwa BL, Kaiser MO, Kaban LB. Occlusal cant in the frontal plane as a reflection of facial asymmetry. J Oral Maxillofac Surg 1997;55:811–6. discussion 817.

[14] Wolford LM, Bennett MA, Rafferty CG. Modification of the mandibular ramus sagittal split osteotomy. Oral Surg Oral Med Oral Pathol 1987;64:146–55.

[15] Dawson PE. Centric relation. Its effect on occluso-muscle harmony. Dent Clin North Am 1979;23:169–80.

[16] Sanromán JF, Gonzalez JG, Del Hoyo JA, et al. Morphometric and morphological changes in the temporomandibular joint after orthognathic surgery: a magnetic resonance imaging and computed tomography prospective study. J Craniomaxillofac Surg 1997;25:139–48.

[17] Lindauer SJ, Sabol G, Isaacson RJ, et al. Condylar movement and mandibular rotation during jaw opening. Am J Orthod Dentofacial Orthop 1995;107:573–7.

[18] Kang MG, Yun KI, Kim CH, et al. Postoperative condylar position by sagittal split ramus osteotomy with and without bone graft. J Oral Maxillofac Surg 2010;68:2058–64.

[19] Mendez-Manjon I, Guijarro-Martinez R, Valls-Ontanon A, et al. Early changes in condylar position after mandibular advancement: a three-dimensional analysis. Int J Oral Maxillofac Surg 2016;45:787–92.

[20] Kim YJ, Oh KM, Hong JS, et al. Do patients treated with bimaxillary surgery have more stable condylar positions than those who have undergone single-jaw surgery? J Oral Maxillofac Surg 2012;70: 2143–52.

[21] Takahara N, Kabasawa Y, Sato M, et al. MRI changes in the temporomandibular joint following mandibular setback surgery using sagittal split ramus osteotomy with rigid fixation. CRANIO® 2017; 35:38–45.

[22] Panula K, Somppi M, Finne K, et al. Effects of orthognathic surgery on temporomandibular joint dysfunction. Int J Oral Maxillofac Surg 2000;29:183–7.

[23] Jung H-D, Jung Y-S, Park H-S. The chronologic prevalence of temporomandibular joint disorders associated with bilateral intraoral vertical ramus osteotomy. J Oral Maxillofac Surg 2009;67:797–803.

[24] Ueki K, Marukawa K, Hashiba Y, et al. Assessment of the relationship between the recovery of maximum mandibular opening and the maxillomandibular fixation period after orthognathic surgery. J Oral Maxillofac Surg 2008;66:486–91.

[25] Phillips C, Turvey TA, McMillian A. Surgical orthodontic correction of mandibular deficiency by sagittal osteotomy: clinical and cephalometric analysis of 1-year data. Am J Orthod Dentofacial Orthop 1989;96:501–6.

[26] Mobarak KA, Krogstad O, Espeland L, et al. Long-term stability of mandibular setback surgery: a follow-up of 80 bilateral sagittal split osteotomy patients. Int J Adult Orthodon Orthognath Surg 2000;15: 83–95.

[27] Ueki K, Moroi A, Sotobori M, et al. A hypothesis on the desired postoperative position of the condyle in orthognathic surgery: a review. Oral Surg Oral Med Oral Pathol Oral Radiol 2012;114:567–76.

[28] Costa F, Robiony M, Toro C, et al. Condylar positioning devices for orthognathic surgery: a literature review. Oral Surg Oral Med Oral Pathol Oral Radiol Endod 2008;106:179–90.

[29] Okeson JP. Management of Temporomandibular Disorders and Occlusion-E-Book. Elsevier Mosby; 2014.

[30] McNamara JA Jr, Seligman DA, Okeson JP. Occlusion, orthodontic treatment, and temporomandibular disorders: a review. J Orofac Pain 1995;9:73–91.